

The Adventures of
**Sherlock Moles
& Dr. Watchon**



· Episode 2 ·

with
Ahmed
Sadek
(Egypt)





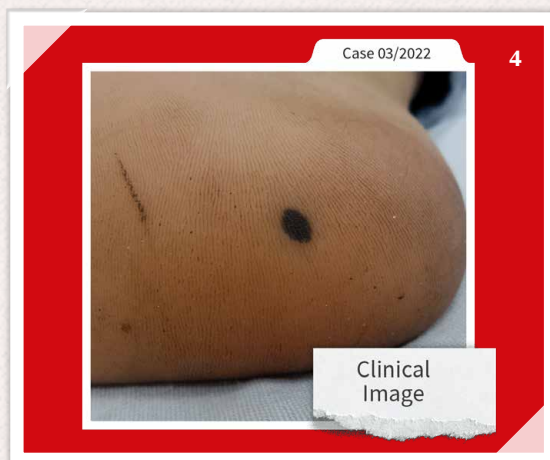
Dr. Ahmed Sadek from **Cairo** has approached **Sherlock Moles** directly with an extraordinary case. The results of his examination have surprised him so much that **Sherlock** consults his colleague **Dr. Watchon**...



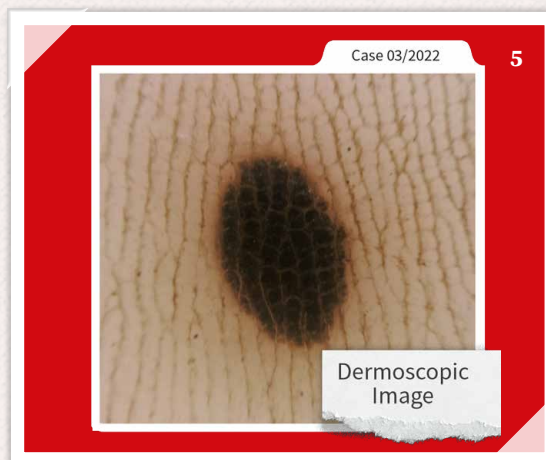It is a beautiful spring morning.
Dr. Watchon is enjoying the peace and quiet, sitting unsuspectingly in his wing chair and browsing through his favorite morning paper, when suddenly...




... Sherlock Moles enters the room.
„**Dr. Watchon** – I have a very interesting case here from **Dr. Sadek**. This **27-year-old patient** has had this lesion **for only three weeks**, and it was painful at the beginning. What do you think of it?“



„Hmm, at first glance a **harmless birthmark**.
Let me see the **magnification!**“



„Hmmm... again – not particularly suspicious. I see a **black oval lesion** with the **medicam 1000s**. It appears as if there is a **slight red hue peri-lesionally**, but...”

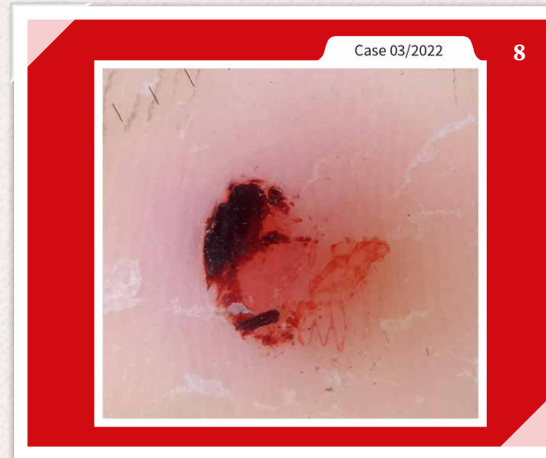

„**Sherlock, are you kidding me?**
That looks perfectly normal.
This is not a case for you, Mr. Moles...“



7

„Oh really? **Well, take a closer look.**
Sometimes you have to **scratch the surface** –literally.“



Case 03/2022


8

„You see, **Watchon?** By **ablating the surface** of the skin, the lesion has almost disappeared, leaving a more distinct **reddish coloration** that clearly suggests a **sub-corneal hematoma**.



9

„A **deep-seated hematoma**?
I would never have guessed **THAT** after the first two pictures! **How did you...?**“



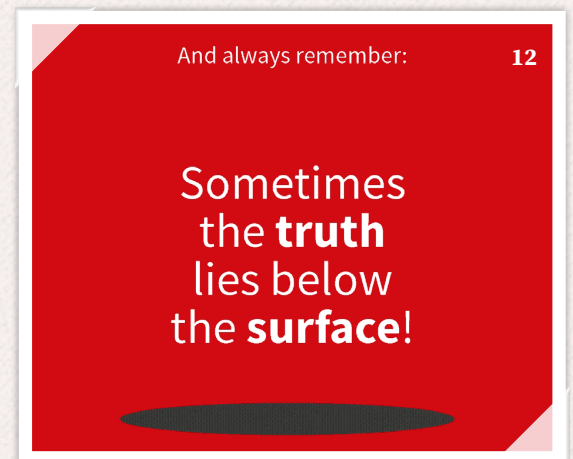10

Well, my dear Watchon – **sometimes you have to remove the obvious first to get to the bottom of it** and then **take a deep dermoscopic look beneath the skin!**



11

Once again, **Sherlock Moles** and **Dr. Watchon** saved the day.



12

And always remember:

Sometimes
the **truth**
lies below
the **surface!**

The End.

Additional Case A

by Dr. Ahmed Sadek

Here, Sherlock Moles & Dr. Watchon will present another case of Dr. Ahmed Sadek.

It is also a **dark plantar lesion**, located on the **sole of the foot**.

This **male patient** at the **age of 42** is not a high-risk patient. He had neither melanoma in his past nor skin cancer cases among family members.

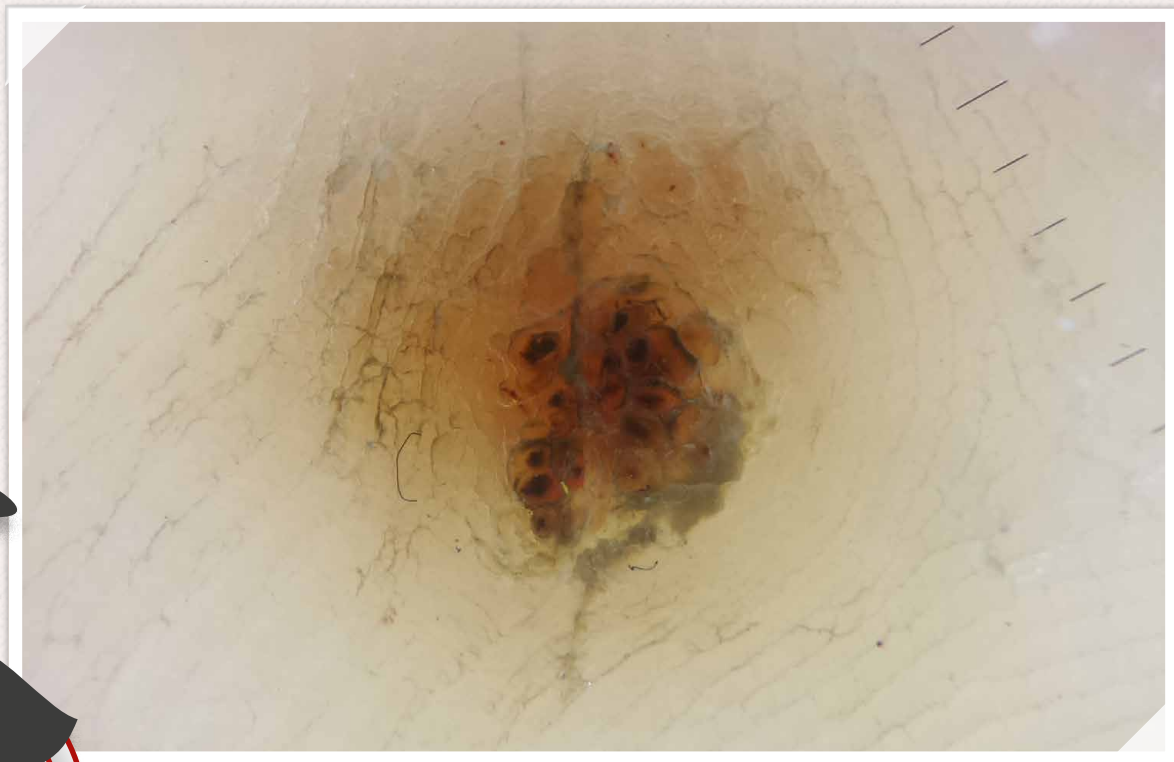
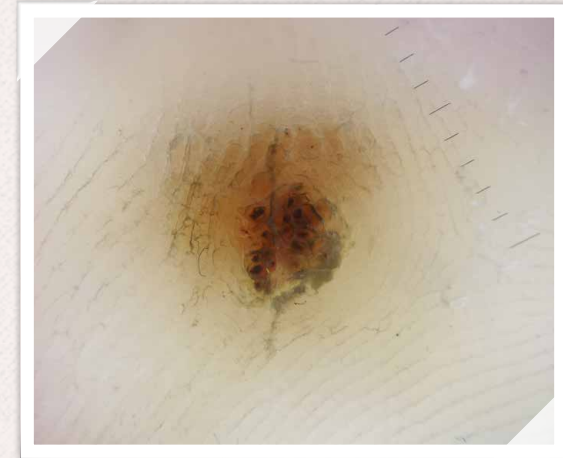
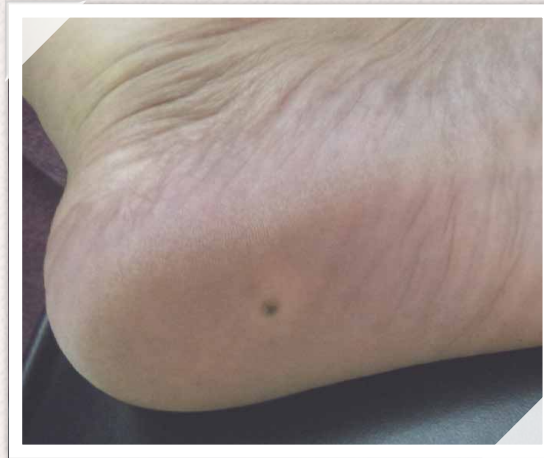This patient consulted Dr. Ahmed Sadek and gave him the information that this **painful lesion** appeared **three months ago** and it is **slightly progressive**.

What would be your diagnosis?

Dr. Sadek examined this lesion with his **medicam 1000s** from FotoFinder and took this dermoscopic image.

The magnification made the diagnosis clear:

Apparently a **plantar wart** with the **thrombosed blood vessels** and the loss of the normal skin markings.



Additional Case B

by Dr. Ahmed Sadek

This is another case which our Mole Detectives do not want to withhold:

Dr. Sadek examined a **53 year old male patient**. During the examination, a **lesion on the sole of the foot** is particularly striking: **dark and apparently bordered**.

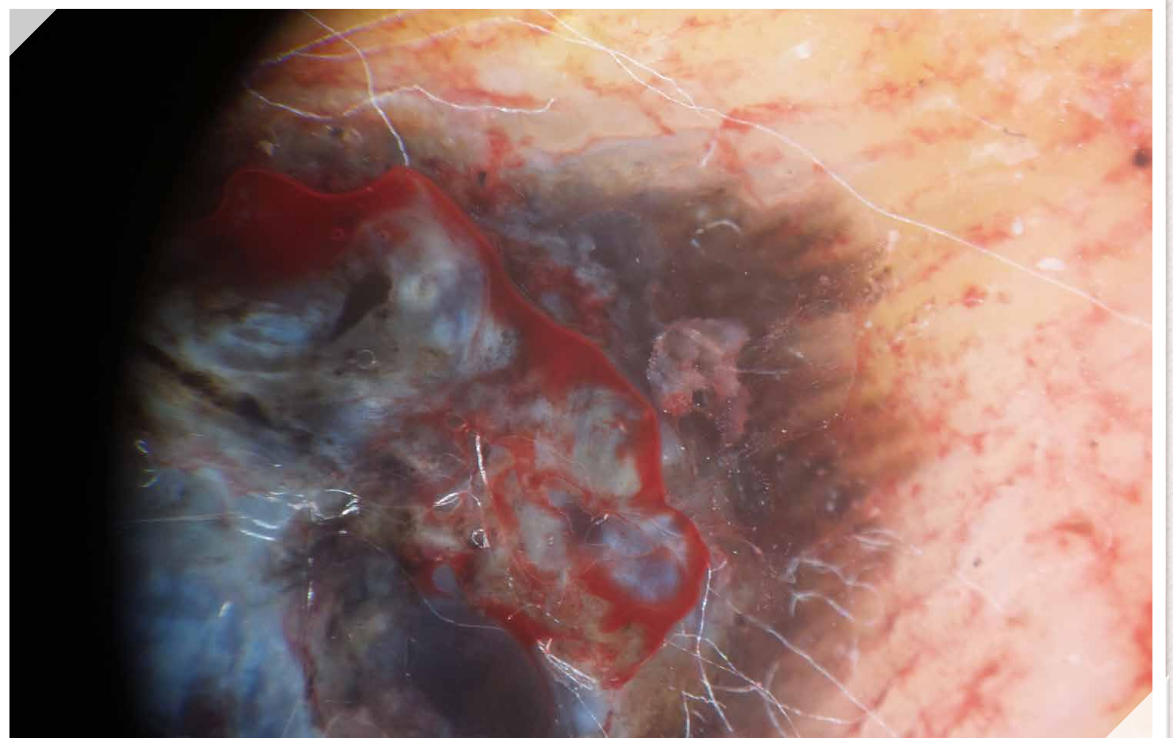
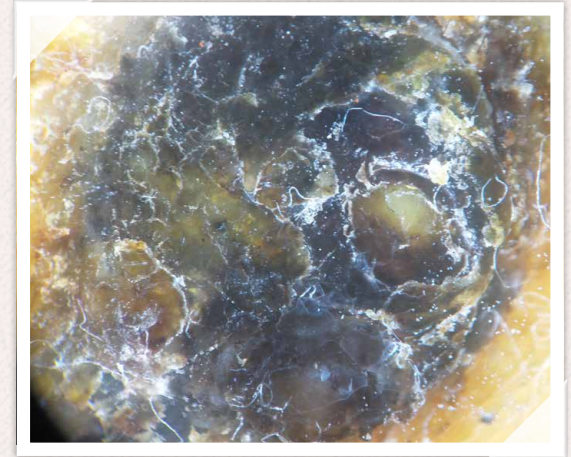
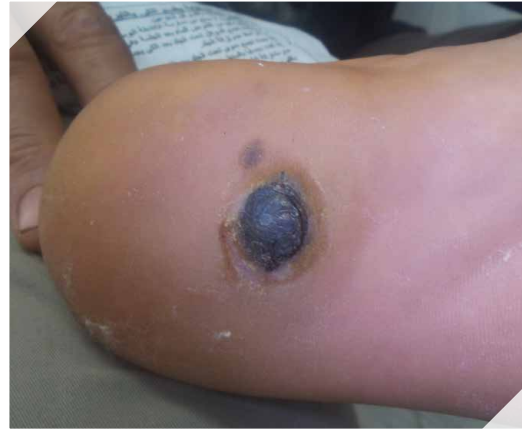The patient is not a high-risk patient and has no history of melanoma, neither in the past nor in his family. According to the patient, he has had this **painful lesion** for about **three years** already and it is **slowly growing**.

What do you think about it?

Within the dermoscopic examination with the **medicam 1000s**, Dr. Sadek detects a **black crusted lesion** with **irregular borders** which is also inconclusive.

He decides to take a deeper look under the skin of the patient: By skin paring with a **surgical blade** which revealed totally **chaotic lesion** within the new dermoscopy image: **homogenous bluish foci** in the center and **parallel ridge pattern** in the periphery.

Now, the diagnosis was clear:
It is an acral melanoma!



You want to share
your case in the
„Adventures of Sherlock
Moles & Dr. Watchon“?

Send us your outstanding
case with a description and
the clinical as well as the
dermoscopy pictures to
marketing@fotofinder.de!

FotoFinder Systems GmbH

📍 Industriestraße 12
84364 Bad Bimbach
Germany

☎ +49 8563 97720-0

📠 +49 8563 97720-10

✉ info@fotofinder.de

🌐 www.fotofinder.de

Editorial:

Kathrin Niemela
Elena Zinner
Martin Baumgartner

Design:

Andreas 'Hanni' Honisch
Florian Forster

© 2022 FotoFinder®
All rights reserved.

